

Supersizing the Penis Following Penile Prosthesis Implantation

Osama Shaeer, MD

Department of Andrology, Kasr El Aini Faculty of Medicine, Cairo University, Egypt

DOI: 10.1111/j.1743-6109.2010.01723.x

ABSTRACT

Introduction. Following implantation of a penile prosthesis, some couples are dissatisfied with penile length, girth, shaft, or glans engorgement. This may be delusional because of the procedure per se or preexisting risk factors such as neglected priapism, Peyronie's disease, radical prostatectomy, or overhanging suprapubic fat.

Aim. In this work, we try to enhance penile size in patients dissatisfied with its dimensions following implantation of a penile prosthesis, using various augmentation techniques.

Methods. Eighteen patients who have had penile prostheses implanted were enrolled in this study based on dissatisfaction with penile size. The complaint was relieved by counseling and administration of PDE5 inhibitors in seven patients. Two patients had elongation, girth augmentation, and glans injection; six had elongation and girth augmentation; and two had elongation and glans injection.

Main Outcome Measures. Penile size, satisfaction, and sexual function.

Results. Average preoperative length and girth were 7.87 cm and 11.62 cm, respectively. Mean postoperative length and girth were 11.62 cm and 14.07 cm. The gain in length (47.6%) and girth (21%) were statistically significant ($P < 0.005$). All patients and partners were satisfied with the results following surgery except one who suffered graft loss.

Conclusion. Implantation of a penile prosthesis may improve penile rigidity, yet may confound couple's satisfaction with penile size to variable degrees. Sex education may alleviate those concerns. In refractory cases, penile augmentation may enhance phallic size and increase patient/partner satisfaction. **Shaeer O. Supersizing the penis following penile prosthesis implantation. J Sex Med 2010;7:2608–2616.**

Key Words. Penile Length; Augmentation; Elongation; Penis; Prosthesis; Implant

Following implantation of a penile prosthesis, there are several possible attitudes of the patient and partner towards the outcome. Among the concerns that some couples express are those of reduced length and/or girth of the penis, and consequent dissatisfaction of the patient and/or partner. Decrease in size may sometimes be a mental impression due to unrealistic expectations, poor counseling, or dysmorphophobia. Alternatively, diminished phallic size may be real and due to the inherent nature of the procedure or to a preexisting pathology. The latter includes cases of fibrosis following radiotherapy, neglected priapism, and Peyronie's disease, all of which exhibit shortening and/or narrowing, or cases with overhanging suprapubic fat leading to concealment. In such cases, diminished size is not a result of the

procedure per se, but rather due to an ignored preexisting complaint of undersized phallus, shadowed by erectile dysfunction (ED), a complaint that the physician failed to recognize and address. On the other hand, actual diminution in size may be iatrogenic, caused by the procedure itself. Some andrologists decline from implanting the maximum possible length or girth of cylinders/rods, especially in diabetic patients and those with corporal fibrosis. Implant length is determined according to the stretched length, which is less than the actual erect length. In the same context is the phenomenon of the "pencil-like penis" caused by loss of complementary erection. This is more pronounced with semirigid in comparison to inflatable implants, and in cases with fibrosis compared with those without [1,2]. However, the

negative effect of implantation on penile size is still a point of debate [3,4].

Whether or not there is a good reason behind the couple's concern, the couple may find the outcome disappointing and even worse; mostly irreversible, despite the andrologist's point of view of the procedure being successful and being the only resort for the refractory ED that the patient had been suffering.

In this work, we try to enhance penile size in patients dissatisfied with its dimensions following implantation of a penile prosthesis, using various augmentation techniques, selected for each patient independently according to his physical state and personal complaints.

Patients and Methods

This study included 24 patients who were dissatisfied with penile size after at least 1 year of regular sexual practice following penile prosthesis implantation. Initial implantation was carried out by a third party prior to presentation. Upon initial examination, the inflated/extended prosthesis reached the glans penis up to the junction between the proximal third and distal two thirds in all patients indicating that the length implanted was probably correct. All patients had one or more of the risk factors for diminished size following implantation: penile concealment with a buried length of at least 3 cm, radical prostatectomy, Peyronie's disease, or diabetes. Five patients were excluded on account of interpersonal conflicts that we thought would bias the results of our study, leaving a study group of 19 patients.

Initially, patients and partners received thorough sex education as regards sexual positions and techniques, and methods for adaptation with post-implantation penile size during intercourse. Patients complaining of shortening were informed of the normal vaginal depth that is usually met by any length above 8 cm, reducibility of suprapubic fat upon intromission, as well as positions that facilitate intercourse with a shorter penis including the female superior position, and full hip flexion and abduction on part of the female partner in the missionary position. Couples complaining of dissatisfactory girth were informed of the how-to and benefits of pelvic floor muscle training for the female partner. Sildenafil citrate was prescribed on "per demand" basis, one hour before intended coitus for cases suffering a cold glans or loss of complementary erection, having no contraindication for PDE5-inhibitors therapy. Patients were

given a 6-month period in a trial to adapt thereafter. During this period, one patient dropped follow-up. The total number of cases was therefore 18. Only patients who were still dissatisfied with penile size (N = 11) proceeded to surgery.

Prior to surgery, all patients signed a written informed consent detailing the possible outcome and complications including infection and failure of surgery to enhance satisfaction. All eleven patients were dissatisfied with penile length, eight were dissatisfied with girth and four with the size and engorgement properties of the glans. Accordingly, one had elongation; two patients had elongation, girth augmentation, and glans injection; six had elongation and girth augmentation; and two had elongation and glans injection (Table 1). Pre- and post-augmentation penile size was recorded. Length was measured from pubic skin surface to the tip. Circumference in the non-aroused state, measured by tape, was adopted as girth (Table 1).

Satisfaction was measured after Mulhal et al. (2003) [5] using the Erectile Dysfunction Inventory of Treatment Satisfaction (EDITS) [6] and the International Index of Erectile Function (IIEF) [7] instruments, administered before augmentation surgery and at 12 months afterwards. Satisfaction was also measured by a simple question: "are you satisfied with your sexual life with the prosthesis implanted" (Table 2).

Elongation was performed by suprapubic lipectomy [8]. A semicircular incision was cut in the pubic skin (Figure 1). A skin flap was dissected with its base at the root of the penis (Figure 2). Whenever possible, and if girth augmentation was intended in the same setting, the superficial external pudendal vessels were identified and preserved. The fundiform and suspensory ligaments were released by sharp dissection (Figure 2). The extent and depth of release was discussed with the patients prior to surgery to avoid undesirable changes in the angle of the erect penis to the abdomen. Accordingly, partial resection was adopted to maintain the preoperative angle. The spermatic cords were identified and marked by tape. A skin-fat ellipse was excised from the scrotal neck (scrotal folds overlying the pubic tubercles) on either sides. Pubic fat was excised from the pubic incision upwards, up to the abdominal crease and down to the rectus sheath (Figure 3). The skin flap was affixed to the pubis. Excess pubic skin was excised (Figure 4). A vacuum drain was inserted. Skin and subcutaneous tissue were sealed in a circular suture line (Figure 5). Pressure bandage was applied to the pubic region. Patients were

Table 1 Pre- and postoperative length and girth

	Preoperative		Postoperative		Procedure performed				
	Length*	Girth†	Length*	Girth†	Elongation	Girth augmentation	Glans Injection	Prosthesis	Risk factor for shortening
1	9	11	11.2	15	✓	✓		Semirigid	Concealment
2	10	12	15	15	✓	✓		Semirigid	Concealment
3	7	10.5	10	14.3	✓	✓	✓	Semirigid	Peyronie's Diabetes
4	10.2	10.8	12	11	✓	✓		Semirigid	
5	6	10	9.5	14	✓	✓		Semirigid	Concealment
6	4	10	10.3	16	✓	✓	✓	Semirigid	Concealment
7	5	11	14	14	✓	✓		Semirigid	Concealment
8	8	12	11	15	✓	✓		Inflatable	Prostatectomy Peyronie's Diabetes
9	10	14	13	14	✓			Inflatable	Concealment
10	9	13.5	13.4	13.5	✓		✓	Inflatable	Concealment
11	8.4	13	10.8	13	✓		✓	Inflatable	Concealment
Average	7.87	11.62	11.62	14.07					
P value	0.00014726	0.0001941310							

*Length measured from pubic skin surface to tip of the glans, standing upright.
†Girth measured in terms of circumference in the non-aroused state.

discharged in the same day. The suction drain was left in place for 2–4 days.

Girth augmentation was performed using the tissues excised from the pubic region as a dermal-fat graft (Figure 4). The graft was trimmed to a thickness of 1 cm of dermis and fat. Through the aforementioned pubic incision, a tunnel was dissected subcutaneously along the dorsum and lateral sides of the penis, making sure adequate Dartos muscle is maintained along with penile skin so as not to compromise vascularity. A circumferential subcoronal incision was cut and the distal penile skin was dissected off of the shaft. The graft was laid in the developed plane and secured to the tunica albuginea (Figure 6). Incisions were closed (Figures 5 and 7).

Glans injection was performed using polyacrylamide gel injected subcutaneously through one puncture point, through which the needle changed direction to inject different planes and aspects of the glans (fanning technique). The injection site was sealed by 5/0 vicryl to prevent seeping of the gel and/or bleeding (Figure 8).

In all cases, parental antibiotics were administered starting one day before surgery and for at least 4 days afterwards. Patients were advised to maintain the penis in an erect state for 2 weeks after surgery.

Results

Counseling and sex education were sufficient to enhance the couple's sexual life and satisfaction in 7 out of 18 patients (38.9%). For the remaining 11

patients, one had elongation; two had elongation, girth augmentation, and injection; six had elongation and girth augmentation; and two had elongation and glans injection. Average preoperative length and girth were 7.87 cm and 11.62 cm, respectively. At 12 months post augmentation, mean postoperative length and girth were 11.62 cm and 14.07 cm. The gain in length (47.6%) and girth (21%) were statistically significant ($P < 0.005$) (Table 1). As regards glans injection, we could not find an objective measuring technique to evaluate the gain in volume, and we had to rely on the subjective impression of the patient which was positive in all cases injected until the injected material faded by the fifth month on average.

All patients were satisfied with the results following surgery (Figure 9) except one who suffered graft loss. Average pre-augmentation EDITS was 51.6, and average 12-month-post-augmentation EDITS was 85.2, with an increase of 65% that was statistically significant (Table 2). IIEF showed statistically significant improvement in the total score (154%), erectile function domain (289%), and satisfaction domain (163%) (Table 2; Figure 10).

Patients who have had glans injection complained about the short-lived improvement and the need for repeated injection if the desired effect was to be maintained, despite preoperative counseling in this regard. Glans augmentation lasted for an average of 5 months. As regards girth augmentation, only one patient suffered total graft loss, requiring surgical removal of the necrotic tissue. Otherwise, there was a mild decrease in

Table 2 Pre- and postoperative satisfaction

	Pre-augmentation				Post-augmentation					
	EDITS	Satisfied?	IIEF total	IIEF erectile function	IIEF-Satisfaction	EDITS	Satisfied?	IIEF Total	IIEF erectile function	IIEF-satisfaction
1	48	Dissatisfied	24	5	6	88	Satisfied	63	26	15
2	51	Dissatisfied	23	7	7	89	Satisfied	60	24	17
3	47	Dissatisfied	27	6	6	88	Satisfied	69	27	15
4	58	Dissatisfied	25	8	6	60	Dissatisfied	40	12	10
5	48	Dissatisfied	24	5	6	87	Satisfied	62	29	19
6	50	Dissatisfied	22	9	8	89	Satisfied	59	29	17
7	58	Dissatisfied	28	6	5	86	Satisfied	68	27	18
8	47	Dissatisfied	24	7	5	88	Satisfied	58	28	16
9	58	Dissatisfied	27	8	7	87	Satisfied	70	29	19
10	56	Dissatisfied	23	5	8	88	Satisfied	72	28	19
11	47	Dissatisfied	22	7	5	88	Satisfied	64	25	17
Average	51.63636364		24.45454545	6.636363636	6.272727273	85.2727273		62.27273	25.81818	16.54545
P value	0.000000001		0.000000000	0.000000000	0.000000001					

IIEF = International Index of Erectile Function; EDITS = Erectile Dysfunction Inventory of Treatment Satisfaction.

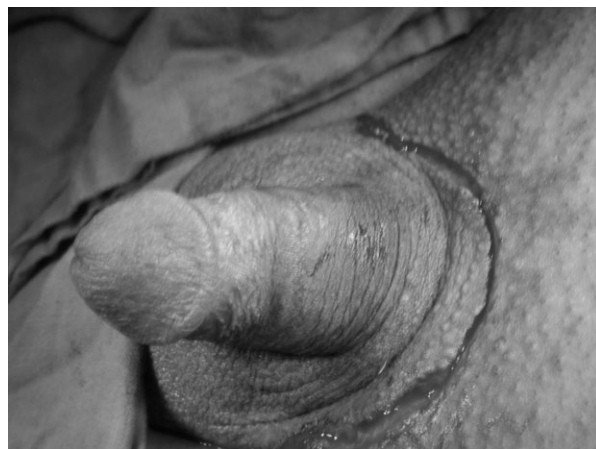

Figure 1 Circumferential incision.

perimeter in the range of 10% when comparing the immediately postoperative girth to 1 year later. In cases of elongation, no subsequent shortening was noted. Only one patient found the change in the angle of erection unappealing, but not to the extent of undermining his satisfaction with the results. Although offered and discussed, none of the patients requested penoscrotal web excision.

Postoperative complications included edema in elongation patients, resolving spontaneously within 1–3 months; wound infection in one case of elongation and girth augmentation managed by antibiotics and daily dressing; and the fore-mentioned single case of graft loss.

Discussion

When the outcome of penile prosthesis implantation is excellent according to the surgeon but the

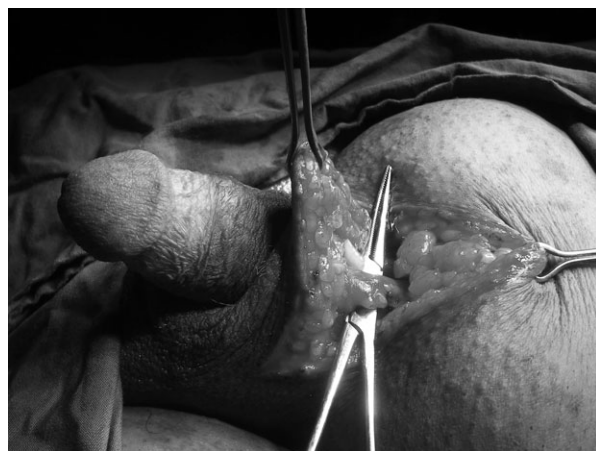

Figure 2 Skin flap development and severing the fundiform ligament.

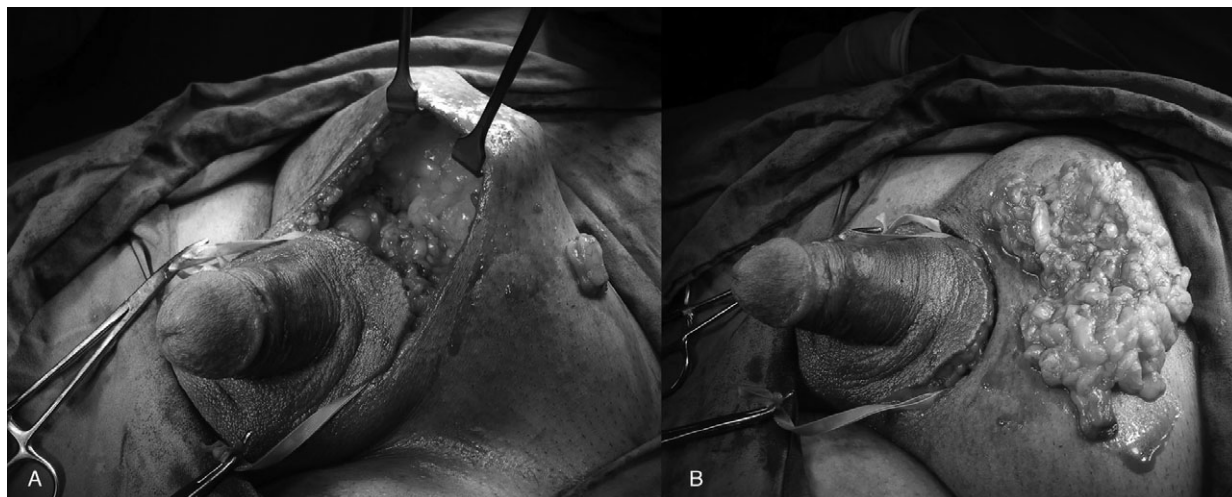


Figure 3 Suprapubic lipectomy: suprapubic region following debulking (A) and excised tissue (B).

patient is displeased, the reason may be that the patient's expectations in terms of penile size have not been met. This may be based on the patient's recall of his erect penile size before ED had set in. Many of those men with ED have not had a normal erection for many months or years, and accordingly a patient's recall of his former erections may sometimes err in the direction of exaggerated length.

Nevertheless, it is likely that penile prosthesis implantation does not provide a prosthetic erection quite as long as a natural erection. In addition, a prosthetic erection does not include glans tumescence and this also contributes to decreased penile length [4]. Shortening is even more severe and obvious in special patient subgroups, especially those with Peyronie's disease, those who have had radical prostatectomy and the obese patients [9].

Regardless of the preexisting pathology, implantation of a penile prosthesis per se may shorten erect penile length. This was particularly evident in a study that compared preoperative erect length as induced by intracavernous injection of papaverine, phentolamine, and prostaglandin E1 to the postimplantation length, which showed shortening in the range of 0.74 ± 0.15 cm at 1 year [1].

The possibly false subjective impression of shortening leading to dissatisfaction was evaluated in a study that included 56 patients who received inflatable penile prosthesis (IPP). There was no difference between flaccid stretched preoperative length and postimplantation length as measured by the authors. Nevertheless, 72% of patients reported shortening. Subjective shortening was more common in patients who had undergone

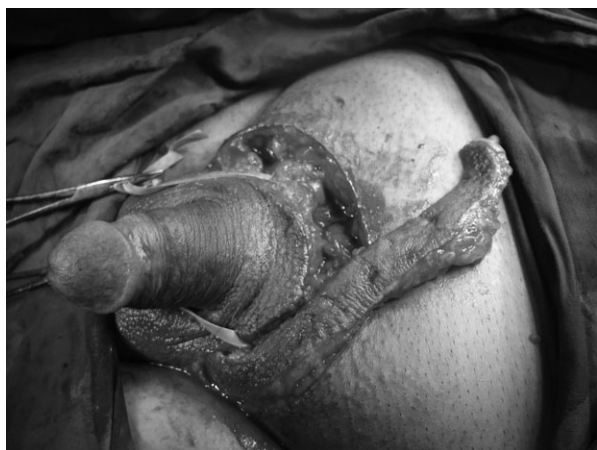

Figure 4 Excision of excess pubic skin.

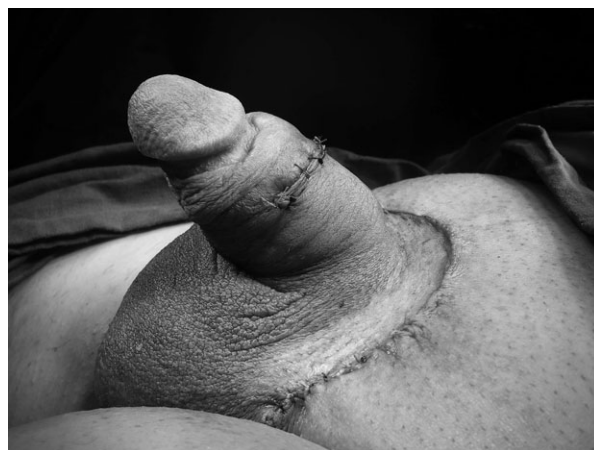

Figure 5 Skin closure.

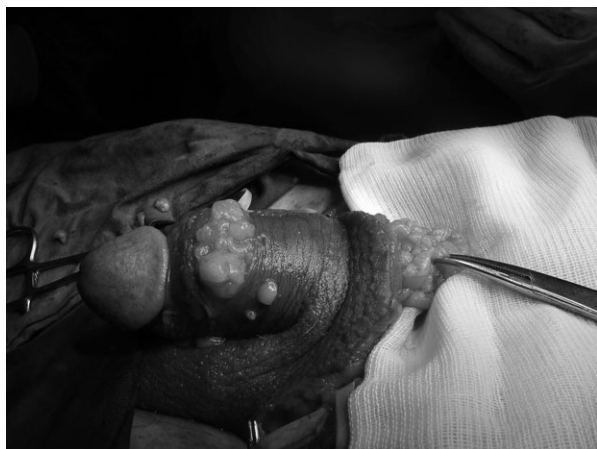

Figure 6 The graft in place.

radical prostatectomy before prosthesis implantation (32%). Men complaining of length loss had lower IIEF satisfaction domain and EDITS scores [3]. We believe that the study by Wang et al. (2009) better reflects length changes following implantation as it adopts erect length [1] rather than flaccid stretched length [3].

A “pencil-like penis” was the term that clearly described the disappointment with penile girth faced by 52% of Peyronie’s patients following implantation of semirigid penile implants. Of the partners, 60% were dissatisfied because of poor penile girth among other factors [2]. While replacement of the semirigid implant with an inflatable is a possible solution, it carries much of

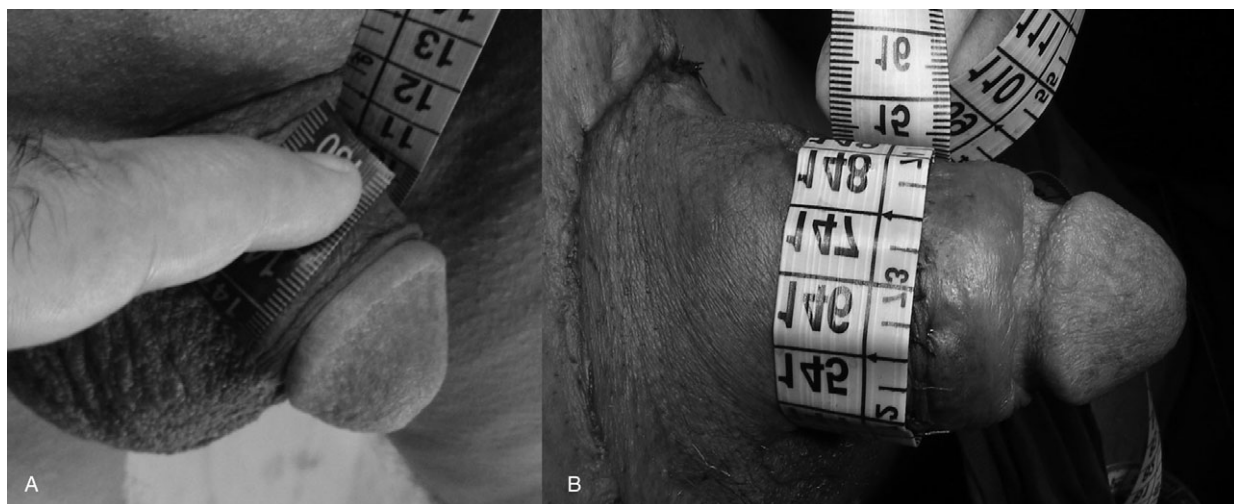


Figure 7 Girth augmentation: before (A) and after (B).

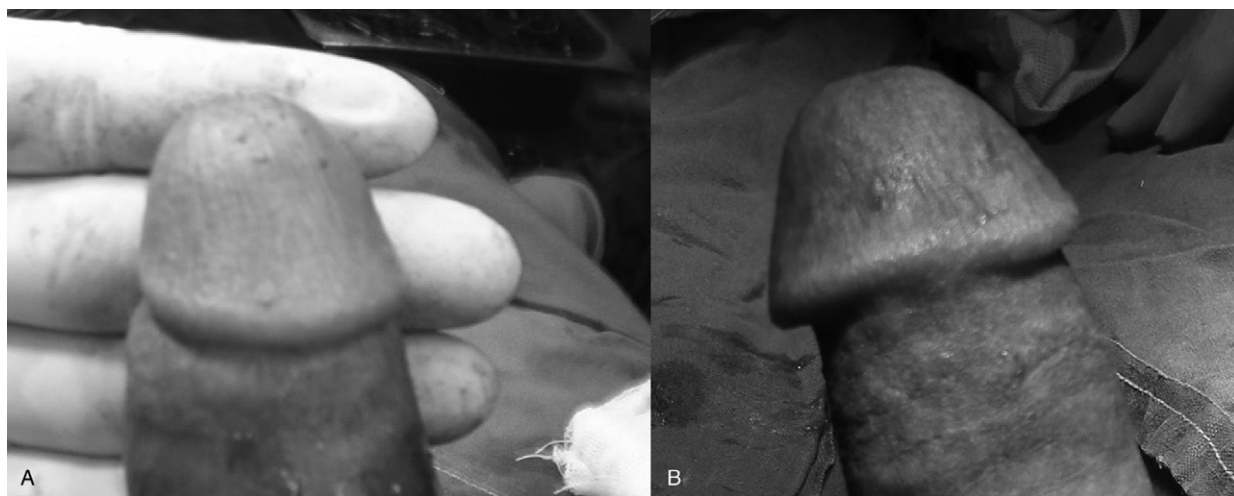

Figure 8 Glans injection: before (A) and after (B), showing the puncture point.

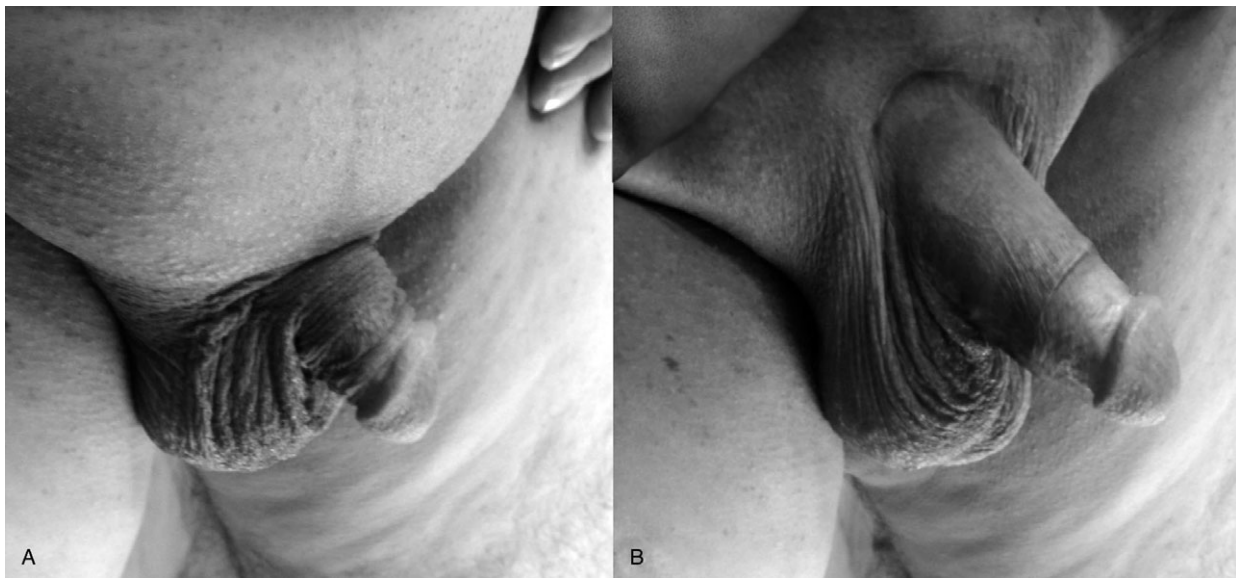

Figure 9 Preoperative state (A) and postoperative state (B).

the same risks met at the first implantation including infection that may necessitate removal of the implant, and still, patient dissatisfaction is possible, especially if the problem of dissatisfaction with girth was there even before ED had set in [2].

Trials to enhance patient satisfaction with penile size following implantation have been reported. Penile elongation by release of the suspensory ligament along with insertion of an IPP was reported to enhance patient satisfaction,

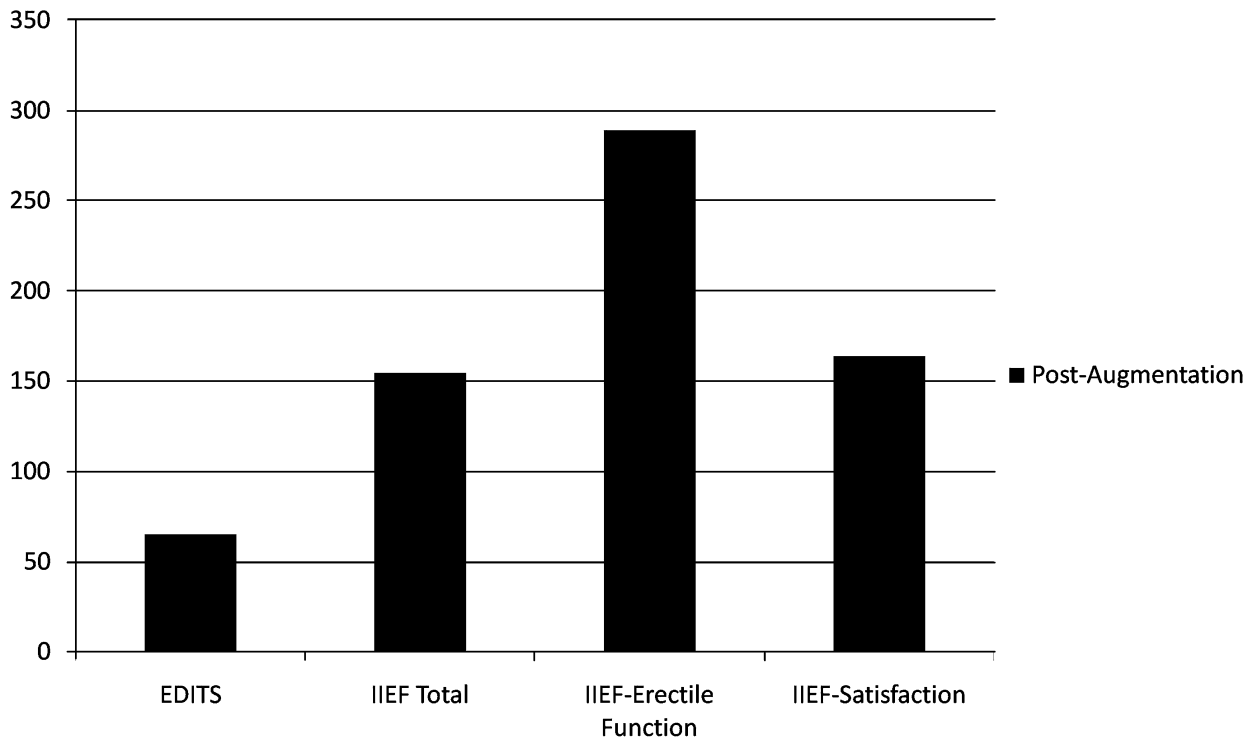


Figure 10 Postoperative sexual function (expressed as percent increase from baseline).

eliminate complaints of shortening and even increase the perceived length in some patients [10]. In patients with high insertion of the scrotum ventrally (penoscrotal web), release of the penoscrotal web was reported to enhance patient perception of penile length and further improve satisfaction [11].

While girth is seldom an issue with the inflatable implants, length and lack of complementary erection remain a problem, which explains dissatisfaction in a sector of patients receiving inflatable implants [1]. An exception may be in the AMS 700 Ultrex (American Medical Systems, Minnetonka, Minnesota, USA) penile prosthesis which produces not only girth expansion but also some length expansion. The initial Ultrex cylinder design released in 1990 permitted more than 20% length expansion. This cylinder was associated with a significantly greater rate of mechanical failure than other IPP cylinders [12] but has been modified to better reliability on the expense of the degree of length expansion: 15–17% [13]. Ultrex penile prosthesis is suitable for men with straight penises and normal elasticity, and not useful in men with limited penile elasticity or Peyronie's disease cases in whom the complaint of shortening is more obvious. The use of the Ultrex prosthesis in properly selected patients produces 1–2 cm of additional length, thus avoiding some of the disappointment due to shortening following implantation [4].

In patients with redundant suprapubic fat, weight loss, and liposuction may resolve the problem partially and not totally, considering the skin redundancy in the suprapubic region that is left behind concealing the penis. Moreover, penile concealment is not only a problem of excess fat, but is multifactorial including penile shaft skin deficiency and Dartos muscle adhesions, all of which can be addressed in formal lipectomy [8]. Nevertheless, weight loss and liposuction are possible options that can be tried upon the patient's will before formal lipectomy.

A prosthetic erection does not include glans tumescence and this also contributes to decreased penile length and dissatisfaction. Intraurethral alprostadil has been used in conjunction with penile prostheses to produce increased blood flow into the glans [14]. Although a response was noted in 23 of 28 men, 12 discontinued its use because of pain. In addition, the on-demand nature of this modality of therapy may add further to the dissatisfaction. Lack of glanular engorgement "cold glans syndrome" and lack of complementary erection were addressed by administration of sildenafil

citrate. Responders reported significantly greater satisfaction scores than with an implant alone [15]. Again, those who are not content with the on-demand therapy following implantation as well as sildenafil citrate nonresponders would not benefit from this option.

In addition to the above-mentioned solutions, our approach of revealing/elongating the penis, increasing girth and/or glans augmentation has resulted in true enhancement of the cosmetic aspect and reflected positively on patient satisfaction and sexual function. It has been reported that satisfaction with penile prosthesis changes over time [5], which is why we preferred to record satisfaction with the implant long enough after both the initial implantation procedure and the subsequent augmentation procedure. The complications were few. Despite the single incident of graft loss, girth augmentation with grafts was more reliable than usual probably because of immobilization (continuous erection possible with a prosthesis implanted), contrary to a normal penis, where repeated erection and detumescence would possible defer graft take resulting in higher complication rates [16] than we report in this series. Nevertheless, the possible disappointment upon graft loss, change in the angle of erection or absorption of the injection gel should be taken into consideration when deciding for surgery, not to mention other complications such as wound infection that may theoretically speaking reach the prosthesis, blood, or lymphatic borne, which is why preoperative, intra- and postoperative antibiotic coverage is a necessary safety measure. Counseling, sex education, and PDE5 inhibitors therapy may in many cases help alleviate concerns, enhance sexual function, and promote couple satisfaction. In our series, this sufficed in 7 out of 18 cases.

We believe that before prosthesis implantation, length and girth upon artificial erection should be assessed and documented. Patients should be asked if they had concerns about penile length or girth before or after they were afflicted by ED. They should be warned about the possibility of decline in length, or girth, the possibility of loss of complementary erection, and the phenomenon of cold glans, and this should be documented in the preoperative consent. Risk factors for dissatisfaction with penile size following implantation include penile concealment, radical prostatectomy, Peyronie's disease, and diabetes. In afflicted patients, the fore mentioned measures should be adopted even more strictly. Thorough and

relevant sex education should be a fundamental part of preoperative and postoperative counseling upon prosthesis implantation. This may in many cases avoid or alleviate dissatisfaction with the results. Surgical solutions for enhancing penile dimensions following implantation may be discussed with the patient whether before implantation or afterwards in case of dissatisfaction.

Conclusion

Implantation of a penile prosthesis may improve penile rigidity, yet may confound couple's satisfaction with penile size to variable degrees. Sex education may alleviate those concerns. In refractory cases, penile augmentation may enhance phallic size, increase patient satisfaction and enhance sexual function.

Corresponding Author: Prof. Dr. Osama Kamal Zaki Shaeer, MD, 21 Gaber Ibn Hayan St., Dokki, P.O.Box: 47 Bab El-Louk, 11513, Cairo, Egypt, 12311 ARE. Tel: (202) 33359047 (202) 33374360; Fax: (202) 37605181; E-mail: dr.osama@alrijal.com

Conflict of Interest: None declared.

Statement of Authorship

Category 1

(a) Conception and Design

Osama Shaeer

(b) Acquisition of Data

Osama Shaeer

(c) Analysis and Interpretation of Data

Osama Shaeer

Category 2

(a) Drafting the Article

Osama Shaeer

(b) Revising It for Intellectual Content

Osama Shaeer

Category 3

(a) Final Approval of the Completed Article

Osama Shaeer

References

- 1 Wang R, Howard GE, Hoang A, Yuan JH, Lin HC, Dai YT. Prospective and long-term evaluation of erect penile length obtained with inflatable penile prosthesis to that induced by intracavernosal injection. *Asian J Androl* 2009;11:411–5.
- 2 Montorsi F, Guazzoni G, Bergamaschi F, Rigatti P. Patient-partner satisfaction with semirigid penile prostheses for Peyronie's disease: A 5-year followup study. *J Urol* 1993;150:1819–21.
- 3 Deveci S, Martin D, Parker M, Mulhall JP. Penile length alterations following penile prosthesis surgery. *Eur Urol* 2007;51:1128–31.
- 4 Montague DK. Penile prosthesis implantation: Size matters. *Eur Urol* 2007;51:887–8.
- 5 Mulhall JP, Ahmed A, Branch J, Parker M. Serial assessment of efficacy and satisfaction profiles following penile prosthesis surgery. *J Urol* 2003;169:1429–33.
- 6 Althof SE, Corty EW, Levine SB, Burnett AL, McVary K, Stecher V, Seftel AD. EDITS: Development of questionnaires for evaluating satisfaction with treatments for erectile dysfunction. *Urology* 1999;53:793–9.
- 7 Rosen RC, Riley A, Wagner G, Osterloh IH, Kirkpatrick J, Mishra A. The international index of erectile function (IIEF): A multidimensional scale for assessment of erectile dysfunction. *Urology* 1997;49:822–30.
- 8 Shaeer O, Shaeer K. Revealing the buried penis in adults. *J Sex Med* 2009;6:876–85.
- 9 Akin-Olugbade O, Parker M, Guhring P, Mulhall J. Determinants of patient satisfaction following penile prosthesis surgery. *J Sex Med* 2006;3:743–8.
- 10 Borges F, Hakim L, Kline C. Surgical technique to maintain penile length after insertion of an inflatable penile prosthesis via infrapubic approach. *J Sex Med* 2006;3:550–3.
- 11 Miranda-Sousa A, Keating M, Moreira S, Baker M, Carrion R. Concomitant ventral phalloplasty during penile implant surgery: A novel procedure that optimizes patient satisfaction and their perception of phallic length after penile implant surgery. *J Sex Med* 2007;4:1494–9.
- 12 Daitch JA, Angermeier KW, Lakin MM, Ingleright BJ, Montague DK. Long-term mechanical reliability of AMS 700 series inflatable penile prostheses: Comparison of CX/CXM and Ultrex cylinders. *J Urol* 1997;158:1400–2.
- 13 Milbank AJ, Montague DK, Angermeier KW, Lakin MM, Worley SE. Mechanical failure of the American Medical Systems Ultrex inflatable penile prosthesis: Before and after 1993 structural modification. *J Urol* 2002;167:2502–6.
- 14 Benevides MD, Carson CC. Intraurethral application of alprostadil in patients with failed inflatable penile prosthesis. *J Urol* 2000;163:785–7.
- 15 Mulhall JP, Jahoda A, Aviv N, Valenzuela R, Parker M. The impact of sildenafil citrate on sexual satisfaction profiles in men with a penile prosthesis in situ. *BJU Int* 2004;93:97–9.
- 16 Alter GJ. Penile enlargement surgery. *Tech Urol* 1998;4:70–6.